



## The pleura, diaphragms, and chest wall

Pleural space—when the pleura is too black

---

---

---

---

---

---

### What will I gain from this video?

After watching this video, you will know how to search for and identify a pneumothorax.

---

---

---

---

---

---

### The radiological pleura is abnormal if...

The pleural space becomes visible and the grayscale image is too black, too white, or too black *and* too white .

---

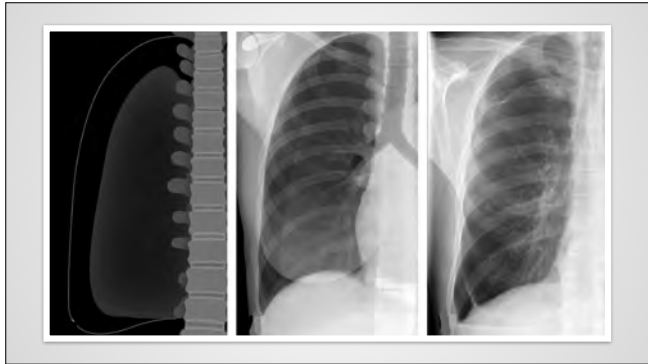
---

---

---

---

---



---

---

---

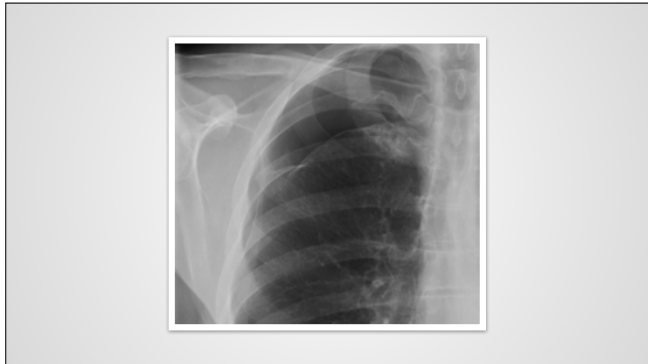---

---

---

---

---



---

---

---

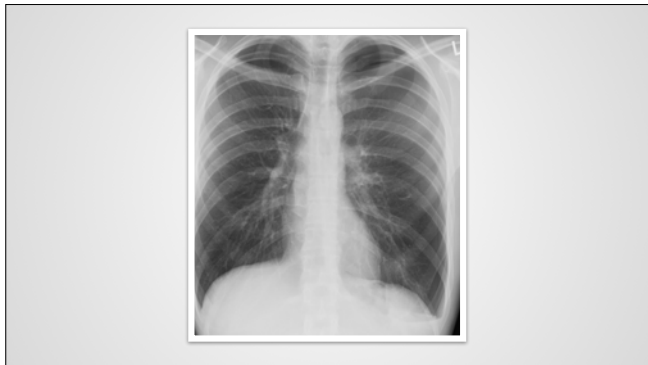---

---

---

---

---



---

---

---

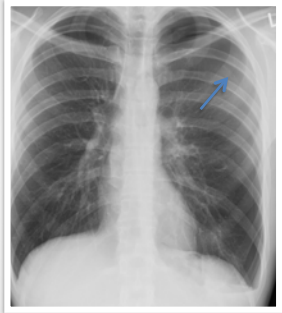
---

---

---

---

---



---

---

---

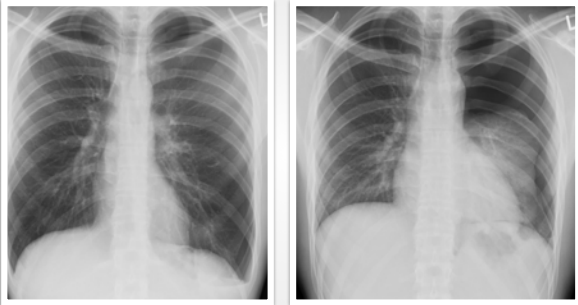
---

---

---

---

---



---

---

---

---

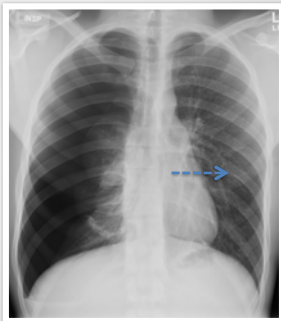
---

---

---

---

**Tension pneumothorax**



---

---

---

---

---

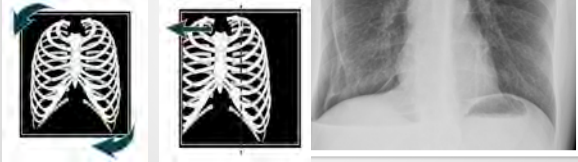
---

---

---

**How to identify a pneumothorax**

STEP 1



---

---

---

---

---

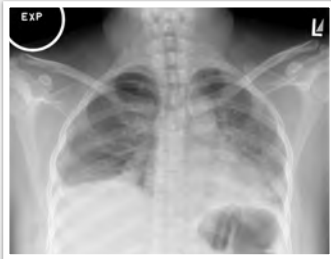---

---

---

**How to identify a pneumothorax**

STEP 2



---

---

---

---

---

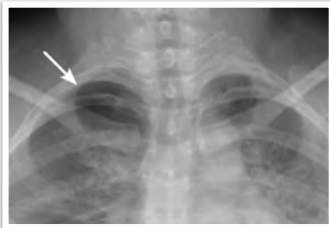---

---

---

**How to identify a pneumothorax**

STEP 3



---

---

---

---

---

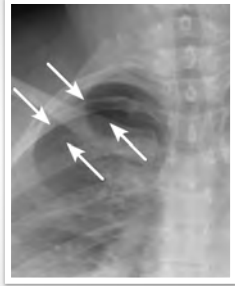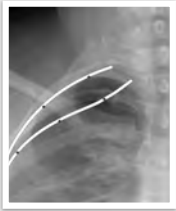---

---

---

**How to identify a pneumothorax**

STEP 4



---

---

---

---

---

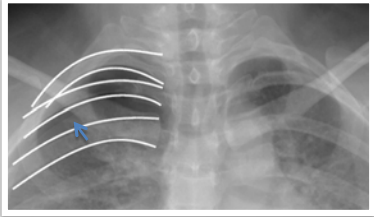
---

---

---

**How to identify a pneumothorax**

STEP 5



---

---

---

---

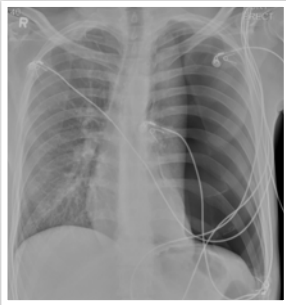
---

---

---

---

**Case 1**



---

---

---

---

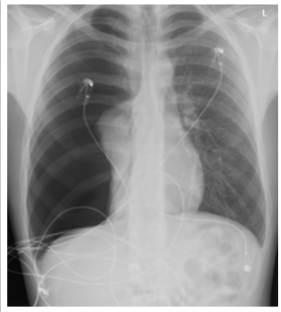
---

---

---

---

**Case 2**



---

---

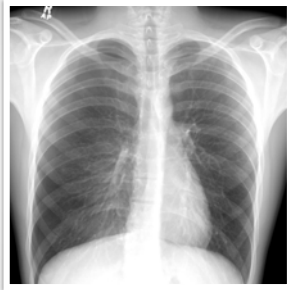---

---

---

---

**Case 3**



---

---

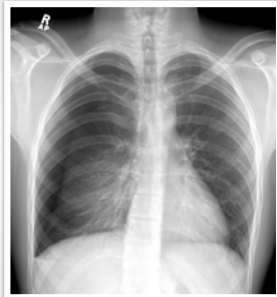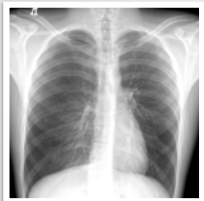---

---

---

---

**Case 3**



---

---

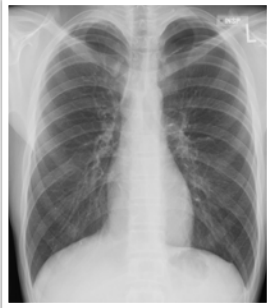---

---

---

---

**Case 4**



---

---

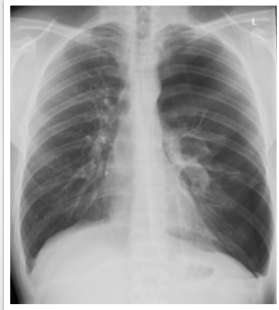---

---

---

---

**Case 5**



---

---

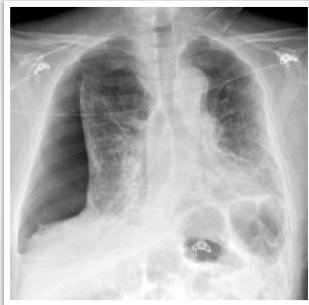
---

---

---

---

**Case 6**



---

---

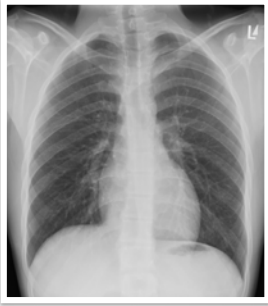
---

---

---

---

**Case 7**



---

---

---

---

---

---

Small pneumothorax can be easily missed.

---

---

---

---

---

---

Small pneumothorax can be easily missed.

Large pneumothorax can be life threatening.

---

---

---

---

---

---



Small pneumothorax can be easily missed.

Large pneumothorax can be life threatening.

Air in the pleural space will rise to the highest point.

---

---

---

---

---

---

Small pneumothorax can be easily missed.

Large pneumothorax can be life threatening.

Air in the pleural space will rise to the highest point.

Thickness of visceral pleura similar to fissure.

---

---

---

---

---

---